

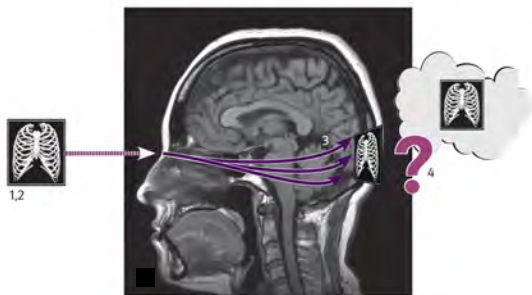



X-ray examinations and the X-ray image

Visual perception

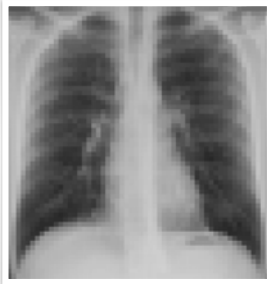What will I gain from this video?

At the end of this video, you will know how to look at a chest X-ray image.



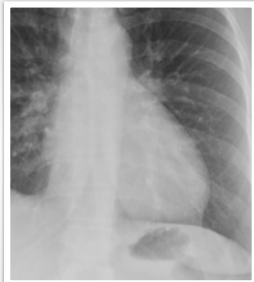


Pattern recognition



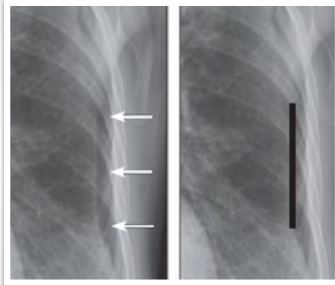
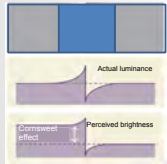
Optical illusions

Mach band effect



Optical illusions

Cornsweet illusion



Outcomes of interpretation—IDEAL

MAXIMUM:

- # true positives
- # true negatives

MINIMUM:

- # false positives
- # false negatives

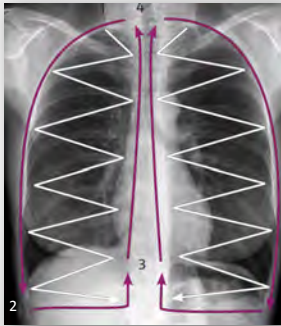Experienced radiologists will miss 20-25% of solitary pulmonary nodules!

Underreading or false negative errors occur five times more often than overreading or false positive errors!

Methods to decrease errors

- Education
- Awareness of the problem
- Research
- Technical standards
- PACS
- Computer-assisted diagnosis (CAD)
- Practice

Visual search



Exercise 1: Find the 3 differences



Exercise 2: 10 differences



normal image



altered image

Accurate interpretation requires:

- ✓ knowledge
- ✓ practice
- ✓ focus
- ✓ consistency
